



**PATIENT**

Dozer Filter

**SPECIES**

Canine

**BREED**

Mastiff

**SEX**

Male Neutered

**AGE**

3 years

**WEIGHT**

116lbs

**INTERPRETED BY**

Maggie Machen Lamy,  
DVM, DACVIM  
(Cardiology)

**IMAGING PERFORMED BY**

Tom McNeill

**HOSPITAL NAME**

SVS Imaging CT

**REFERRING VET**

Dr. Bittner

**INVOICE**

24723

**DATE**

6/10/22

**PRESENTING CLINICAL SIGNS**

History: Patient presented on 6/8/22 for a seizure.

-Abnormal PE/Chem/CBC/UA Results: 6/8- PE normal, CBC WNL CHEM WNL 4DX Neg Gave midazolam and propofol prior to rads. Abdominal Rads NSF. Thoracic Rads NSF, heart/lungs WNL. ECG increased rate about 200bpm. ProBNP (3584).

**RADIOGRAPHIC FINDINGS** \*NOTE: Images submitted for supplemental cardiac information only.  
Normal cardiac silhouette. No obvious evidence of CHF.

**ELECTROCARDIOGRAPHIC FINDINGS** \*Note: Single lead ECGs are evaluated as a rhythm strip. Morphology/MEA cannot be definitively commented on.  
A single lead ECG is available; 25mm/s, 10mm/mV. The average heart rate is 200bpm with a largely regular rhythm. The rhythm is most consistent with a sinus tachycardia, although without any break or rate variation a paroxysmal SVT is not entirely ruled out. The P and QRS morphologies are positive. No ectopic beats, pauses or other dysrhythmias observed.  
ECG diagnosis: Suspect normal sinus tachycardia; paroxysmal SVT is not ruled out.

**ECHOCARDIOGRAM FINDINGS**

2D, m-mode, color flow and doppler imaging is available. Normal mitral valve leaflets with no prolapse into the left atrial lumen. No obvious mitral regurgitation with a normal left atrial dimension. Normal LV diameter with adequate systolic function for this signalment. The tricuspid valve appears normal with no tricuspid regurgitation. Normal right atrial and ventricular diameter and morphology indicating no overt evidence of pulmonary arterial hypertension. The pulmonic and aortic valves are normal in morphology and mobility. Normal pulmonic and aortic outflow velocities with laminar flow. Trace aortic and no pulmonic insufficiency. No pericardial or pleural effusion noted. No obvious cardiac masses.

**CARDIAC CHART**

CANINE CARDIAC PARAMETERS	MR VMAX (m/s)	TR VMAX (m/s)	LA/AO (Boon method)	LA/AO (Heart Base; Swe)	FS (%)	EF (%)	EPSS (cm)
NORMAL PARAMETER	4.5-5.5	<2.7	1.3	<1.6	28-40	40-100	<0.6
PATIENT	NA	NA	1.2	1.2	26	51	0.69
CANINE CARDIAC PARAMETERS	HR (BPM)	AV VMAX (m/s)	PV MAX (m/s)	BODY WEIGHT (kg)	LA 2D short axis Base view (cm)	LVIDd Avg; 2D and m-mode short axis (cm)	LVIDs Avg; 2D and m-mode short axis (cm)
NORMAL PARAMETER	50-100	0.7-1.7	0.7-1.6	BELOW	BELOW	BELOW	BELOW
PATIENT	175	1.3	1.3	52.6	3.5	5.2	3.8
*Normal chamber parameters expressed as a mean value (SD)				3	1.27 (5.3)	2.46 (2.46)	1.36 (5.5)
<b>BODY WEIGHT DEPENDENT PARAMETERS</b>				5	1.40 (4.5)	2.74 (5.2)	1.60 (4.7)
<i>*Note: All measurements based upon multi-modal images and methods. An average value is reported.</i>				10	1.50 (3.8)	3.27 (3.5)	2.06 (3.1)
				15	1.83 (2.0)	3.71 (2.4)	2.43 (2.1)
				20	2.02 (1.9)	4.14 (2.2)	2.80 (2.0)
Adapted from June Boon, Veterinary Echocardiography, 1998				25	2.18 (2.4)	4.48 (2.9)	3.10 (2.5)
Rishniw M and Hollis NE, J Vet Intern Med 2000; 14:429-435				30	2.33 (3.3)	4.83 (3.9)	3.39 (3.4)
Hansson et al, Vet Rad and Ultrasound 2002				35	2.48 (4.3)	5.17 (5.0)	3.69 (4.5)
Bonagura et al. Echocardiography: principles of interpretation, Vet Clin North Am 15:1177, 1995				40	2.62 (5.2)	5.48 (6.1)	3.96 (5.4)



**PATIENT**

	50	2.88 (7.1)	6.07 (8.3)	4.46 (7.4)
--	----	------------	------------	------------

Dozer Filter

**SPECIES**

Canine

**BREED**

Mastiff

**SEX**

Male Neutered

**AGE**

3 years

**WEIGHT**

116lbs

**INTERPRETED BY**

Maggie Machen Lamy,  
DVM, DACVIM  
(Cardiology)

**IMAGING PERFORMED BY**

Tom McNeill

**HOSPITAL NAME**

SVS Imaging CT

**REFERRING VET**

Dr. Bittner

**INVOICE**

24723

**DATE**

6/10/22

**INTERPRETATION OF THE FINDINGS & FURTHER RECOMMENDATIONS**

Overtly normal cardiac dimensions and function, with no obvious dysfunction or dilation of the left heart. A small aortic leak is noted, and a baseline blood pressure is strongly recommended. No significant valvular leaks are visualized, and no evidence of pulmonary hypertension.

The ECG shows a supraventricular tachycardia, however differentiating between sinus and a paroxysmal SVT cannot be determined without more information (assess onset/break, response to vagal maneuver, etc). A sinus tachycardia can have a HR as high as 220bpm depending on the circumstance.

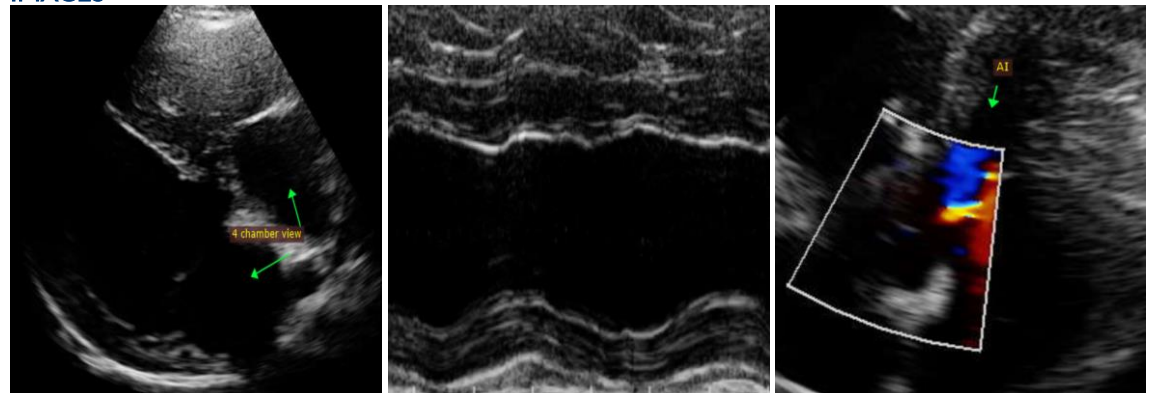
Given what we have here, there are 2 possibilities. First is that a true paroxysmal SVT is occurring which may have led to a syncopal episode (r/o syncope v seizure in the history). The second possibility is that some other issue (systemic, neurologic, etc) caused a seizure and sinus tachycardia is secondary. Further evaluation is advised, including full systemic evaluation (radiographs, echo/AUS, senior labs, etc). Further historical information may be beneficial to determine if syncope or a seizure is more likely. Reassessing the ECG may be useful, performing a vagal maneuver and assessing response, etc. Finally, a holter monitor may be necessary if no systemic issues are identified, to understand the true underlying rhythm in this case. Based upon the information we have, no anti-arrhythmic treatment is indicated at this time.

Monitor for development of a heart murmur, cough, labored breathing, exercise intolerance or collapse episodes.

Plan: Consider full systemic/neurologic evaluation. Further historical information on the episode is recommended. Reassess ECG, response to a vagal maneuver, refer for a 6 lead tracing if tachycardia persists, consider a holter, etc. Baseline BP recommended.

A recheck echocardiogram is recommended should a significant murmur develop, or signs of cardiac compromise be noted in the future.

**IMAGES**



**IMAGING PERFORMED BY**

svsmobileimaging.com 309 - 737 - 3070



EDUCATIONAL TELECONSULTATION SERVICES™

1-800-838-4268 info@sonopath.com SonoPath.com

**PATIENT**

Dozer Filter

**SPECIES**

Canine

**BREED**

Mastiff

**SEX**

Male Neutered

**AGE**

3 years

**WEIGHT**

116lbs

**INTERPRETED BY**

Maggie Machen Lamy,  
DVM, DACVIM  
(Cardiology)

**IMAGING PERFORMED BY**

Tom McNeill

**HOSPITAL NAME**

SVS Imaging CT

**REFERRING VET**

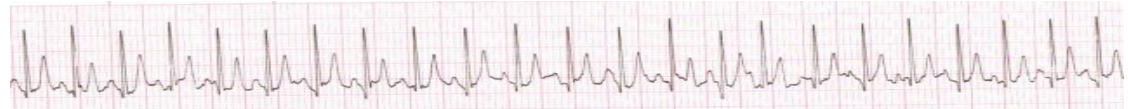Dr. Bittner

**INVOICE**

24723

**DATE**

6/10/22



The information and recommendations provided are based on the images presented by the referring veterinarian. No evaluation can be communicated regarding pathology that was not visible in the image/video clips provided.

Thank you for this referral. If the clinical or image interpretation does not parallel your findings or if I can be of any further assistance, please contact me.

Maggie Machen Lamy, DVM  
Diplomate of the American College of Veterinary Internal Medicine (Cardiology)  
info@sonopath.com